87-e38

YAKIMA RIVER FISH HISTOPATHOLOGY STUDY

Marsha L. Landolt and Richard Kocan
School of Fisheries, University of Washington

March 1987

Submitted to Washington State Department of Ecology
and
Environmental Protection Agency, Region 10

Art Johnson, Washington State Department of Ecology, Contract Officer
Dave Terpening, Environmental Protection Agency, Contract Officer

Environmental Protection Agency Grant No. X000314

ANDREA BEATTY RIDER
Director

STATE OF WASHINGTON

DEPARTMENT OF ECOLOGY

[illegible] Cleanwater Lane [illegible] • Olympia, Washington 98504-[illegible] • [illegible]

MEMORANDUM
March 13, 1987

To: Russ Taylor

From: Art Johnson AJ and Bill Yake BY

Subject: Report on the 1986 Yakima River Fish Histopathology Study

Here is the final report on a pilot project examining the health of fish in the Yakima River. The study was conceived and directed by the Water Quality Investigation Section (WQIS) and funded by EPA Region 10. Dave Terpening was the EPA project officer. The field work was a cooperative effort among WQIS, EPA, and Drs. Marsha Landolt and Richard Kocan of the University of Washington, School of Fisheries, who were contracted to do the histopathological examination.

Histopathology refers to the application of light or electron microscopy to the study of tissue defects. Drs. Landolt and Kocan are recognized experts in this field and have done extensive work in Puget Sound. They did the histopathology for Ecology's Superfund investigation in Commencement Bay.

The impetus for the present study was a desire to further evaluate the significance of elevated levels of chlorinated pesticides in fish from the lower Yakima River (Hopkins et al. 1985, Johnson et al. 1986) and its generally recognized poor water quality. Histopathological examination of fish tissues has proved a valuable tool for identifying contaminated sites in Puget Sound, but the approach had never been extended to state fresh waters. Briefly, the study involved field examination and tissue sampling (blood, spleen, liver, kidney, gonad, and gill) of carp, largescale suckers and a small number of miscellaneous species from the lower Yakima River above Horn Rapids Dam (river mile 20-23), and largescale suckers from the Yakima River Canyon above Rosa Dam (river mile 129). A total of one hundred sixty-seven specimens were examined. Tissue samples were returned to the University of Washington where they were examined microscopically for biological abnormalities. Carp and largescale suckers were selected for study because fish associated with the bottom sediments tend to display a higher frequency of lesions and other abnormalities than species such as trout that live off the bottom.

The results of this rather extensive examination of Yakima River fish are summarized in the attached report as follows:

> "The fish...bore no lesions that suggested widespread contaminant effects. The only organs that might warrant further research were the gonads of common carp. A significant number of female carp bore atretic (degenerating) ovarian follicles. ... Follicular atresia can be caused by a baffling array of factors including environmental conditions (e.g., water temperature, photoperiod, dissolved oxygen), nutritional deficiencies, endocrine disorders, parasitism, and contaminant exposure. Attempting to establish cause and effect relationships under field conditions would be a difficult and expensive undertaking. ... All other organ systems in all species were either unremarkable or bore minor lesions that could be attributed to parasitic and bacterial infections."

Basically, the fish looked healthy. While the findings of this study should not be construed as a clean bill of health for the Yakima River, it does suggest that the types of abnormalities of concern in Puget Sound are not a problem in the Yakima. Furthermore, it appears that the levels of chlorinated pesticides in fish from the Yakima main stem are below thresholds for liver and kidney damage that have been associated with these compounds (Sindermann, 1979; Walsh and Ribelin, 1975).

The histopathology study did not, of course, address other potential water quality-related concerns in the Yakima such as indirect toxic effects on fisheries through reduction in food supply, or sublethal effects such as altered behavior or reduced growth. There remains a concern for effects on aquatic life from the relative high water concentrations of chlorinated pesticides in certain tributaries to the Yakima as described in Johnson et al. (1986).

We think the present study was a worthwhile first attempt to go beyond the usual monitoring effort where contaminant concentrations are measured and reported. Future studies of this type in state freshwaters might best be directed at evaluating a different class of compounds. Aromatic hydrocarbon contamination in Lake Union is currently being considered for study in 1987 or 1988.

AJ:BY:cp

Attachment

REFERENCES

Hopkins, B.S., D.K. Clark, M. Schlender, and M. Stinson, 1985. Basic water monitoring program fish tissue and sediment sampling for 1984, Washington State Dept. Ecology, 85-7, 43 pp.

Johnson, A., D. Norton, and B. Yake, 1986. Occurrence and significance of DDT compounds and other contaminants in fish, water, and sediment from the Yakima River basin. Washington State Dept. Ecology, 86-5, 89 pp.

Sindermann, C.J., 1979. Pollution associated diseases and abnormalities of fish and shellfish: a review. Fishery Bulletin 16(4): 717-749.

Walsh, A.H. and W. E. Ribelin, 1975. The pathology of pesticide poisoning. in G. Migaki (ed.) The Pathology of Fishes. pp.550-594, Univ. Wisc. Press, Madison, WI.

INTRODUCTION

The occurrence and significance of biological abnormalities arising through contaminant exposure has been intensively studied in marine fish from Washington State (Malins et al., 1982); however, the health of the state's freshwater species has not been investigated. Studies of contaminated lakes and rivers in other regions of the United States have revealed the presence of pathological conditions in a variety of aquatic fish species. Dawe et al. (1964) observed bile duct neoplasms and hepatocellular nodules in white suckers (Catostomus commersonii) and brown bullheads (Ictalurus nebulosus) of Deep Creek, Maryland. Sonstegard (1977) noted the presence of oral papillomas in white suckers inhabiting polluted areas of Lake Ontario, and, through retrospective studies of museum specimens, he was able to document a dramatic increase in the frequency of gonadal neoplasms among carp-goldfish hybrids of the Great Lakes. Bauman et al. (1982) found hepatic neoplasms in brown bullheads inhabiting a region of Ohio's Black River that was heavily contaminated by aromatic hydrocarbons. High prevalences of hepatocellular carcinoma were also found in Atlantic tomcod (Microgadus tomcod) of the PCB contaminated Hudson River (Smith et al., 1979), as well as in sauger (Stizostedion canadense) and walleye (Stizostedion vitreum) inhabiting lake waters receiving copper mining wastes (Black et al., 1982). Black (1983) was able to bridge the gap separating observational studies, in which causal relationships between contamination and neoplasia are inferred, from experimental studies, in which cause-and-effect relationships are proven. He was able to induce hepatocellular and oral carcinomas in brown bullheads by repeatedly painting captive fish with sediment extract taken from a portion of the Buffalo River, New York, which contained high levels of aromatic hydrocarbons. The induced neoplasms were identical to those that he found in wild bullheads living in the same region of the river.

For the present project, the lower Yakima River was selected as the site for a pilot study of biological abnormalities in freshwater fish of Washington. The site was chosen because of its importance as a fisheries resource, because of its poor water quality, and because of the finding of elevated organochlorine residues in fish which inhabit it. Bottom-feeding species were selected for examination because biological abnormalities have most frequently been detected in fish which live in close association with sediment (Dawe and Harshbarger, 1975). In addition, adult fish were examined rather than juveniles because most cases of contaminant-associated biological abnormalities have been found in mature individuals.

MATERIALS AND METHODS

On July 29, 1986, fifty adult common carp (Cyprinus carpio) and fifty adult largescale suckers (Catostomus macrocheilus) were collected by electroshocking from the lower Yakima River above Horn Rapids Dam (river mile 20-23). Seventeen fish of miscellaneous species were also collected. On July 30, 1986, fifty largescale suckers were collected within the Yakima River Canyon above Rosa Dam (river mile 129). The collection sites are shown in Figure 1.

The fish were placed in live tanks aboard the collecting boat and returned to shore within 20 minutes of capture. They were anesthetized with methane tricaine sulfonate (MS-222), sacrificed by a blow to the head, and assigned an accession number. A blood sample, obtained by caudal vein puncture, was taken from each fish and used to prepare smears for hematological examination. The fish were then measured (total length, mm), weighed (grams), and examined for the presence of visible external defects. At necropsy, five tissues--liver, kidney, spleen, gill, gonad--were excised, examined, and a portion placed in 10 percent neutral buffered formalin.

Blood films were preserved with methanol, air-dried, and stained with Leishman-Giemsa dye. Solid tissues were dehydrated through a graded ethanol series, cleared, embedded in paraffin, and sectioned (5 um) on a rotary microtome. The tissue sections were stained with hematoxylin and eosin for microscopic examination. Pathological conditions were recorded using both verbal descriptions and National Ocean Data Center (NODC) standardized codes. The severity of each lesion was noted as was its distribution.

RESULTS

External Examination--Carp ranged in length from 310 to 585 mm (mean=440 mm), and in weight from 550 to 3,580 g (mean=1,750 g). Females were somewhat more common (54 percent) than males (46 percent). External lesions were seen in only three fish, and consisted of minor skin abrasions or, in one instance, a deformed lip.

Largescale suckers at Horn Rapids Dam ranged in length from 345 to 530 mm (mean=448 mm), and in weight from 550 to 2,035 g (mean=1,152 g). Suckers at the Yakima River Canyon were slightly larger, ranging in length from 385 to 677 mm (mean=479 mm), and in weight from 625 to 2,345 g (mean=1,377 g). Sex ratios were identical at the two sites (68 percent female, 32 percent male). Twenty-six percent of the Horn Rapids suckers had minor integumentary lesions. The lesions were inflammatory foci which appeared to arise through traumatic injuries. Hemorrhagic integumentary lesions were noted in 56 percent of the suckers from the Yakima River Canyon. The lesions were more extensive than those at the previous site. Histological examination of selected integumentary tissues revealed extensive hemorrhagic inflammation extending deep into underlying muscle tissue.

Internal Examination--Upon necropsy, the organs of most fish were unremarkable to the unaided eye. The major exception pertained to carp from Horn Rapids Dam in which 41 percent of the females had significant numbers of necrotic (dead) eggs in the ovary. Histological examination of these ovaries revealed follicular atresia of unknown origin. At the time of necropsy, one female (#27) was described as having a "very bizarre" ovary. Histological examination of the organ revealed that the fish was a hermaphrodite, and that the unusual appearance of the gonad resulted from the co-occurrence of seminal vesicles and ovigerous follicles. In addition to the ovarian lesions,

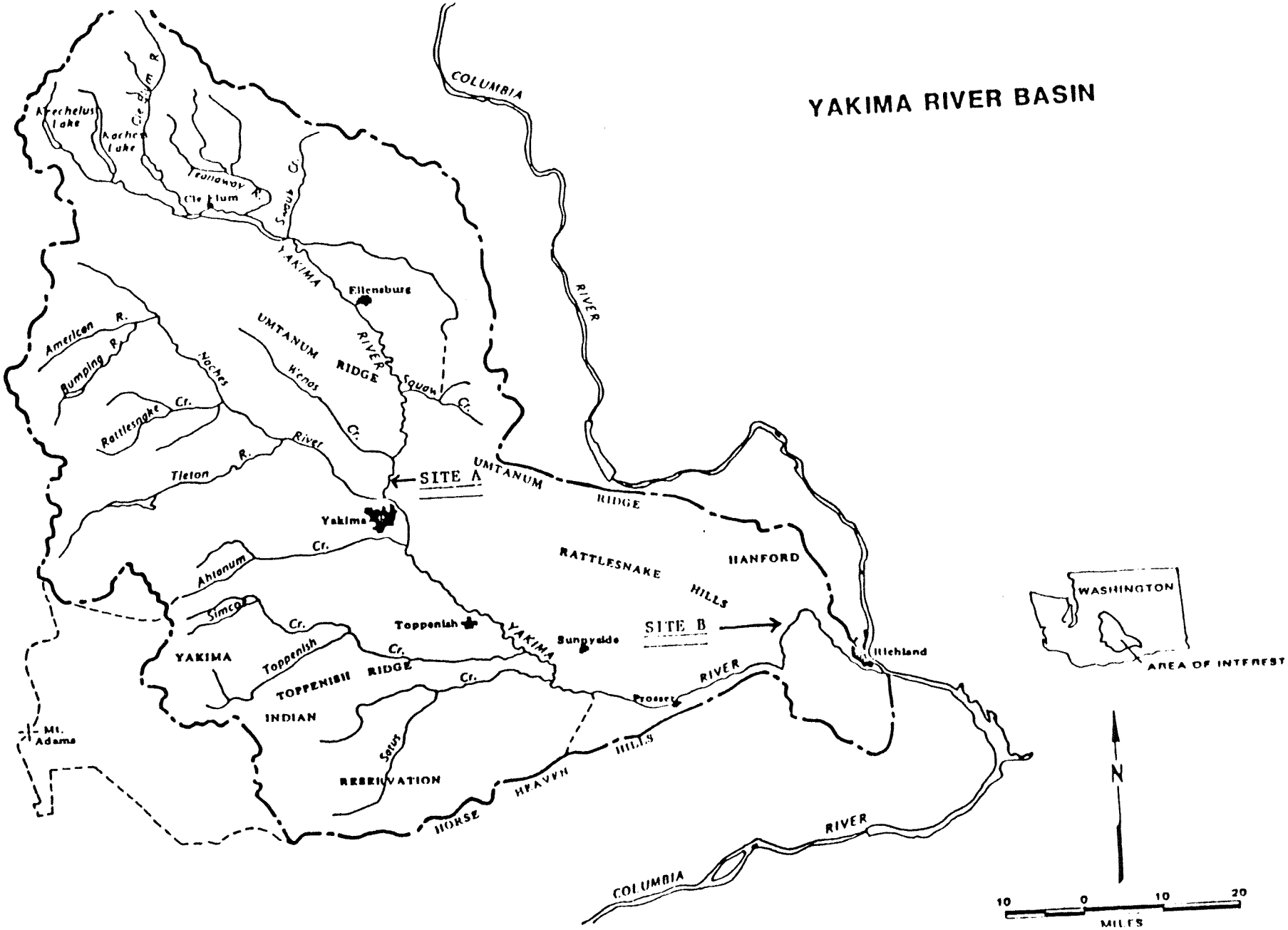

Figure 1. Lower Yakima River collecting sites. Site A is the Yakima Canyon above Rosa Dam. Site B is Horn Rapids Dam.

one male carp (#28) had an enlarged, firm testis. Histological examination revealed that the testicular tissue was extremely fibrotic. Large areas of the organ exhibited parallel arrays of connective tissue matrix and fibroblasts. In addition, there were centrally located necrotic foci which contained pyknotic cells and cells with irregularly condensed chromatin. A few mitotic figures were observed. The appearance of the tissue, the presence of necrotic centers, and the observation of mitotic figures suggested that the lesion was a fibroma (a benign neoplasm of fibroblastic origin).

Carp bore no remarkable lesions with the exception of the previously noted follicular atresia and possible fibroma. Most of the kidney sections contained thyroid centers consisting of colloid-filled follicles. In many fish species, thyroid follicles are found only within cephalic tissues; however, they are a normal component of carp renal tissue. The presence of thyroid centers was noted in the raw data (cysts, code 002), but their occurrence does not represent a pathological defect.

None of the carp tissues, with the possible exception of the previously noted testicular lesion, bore neoplasms or idiopathic conditions which were suggestive of contaminant exposure. On the contrary, the tissues were generally unremarkable or bore minor defects attributable to parasitism and bacterial infection.

Largescale suckers from Horn Rapids Dam enjoyed generally excellent health. The only recurring lesion of any significance was the presence of renal and splenic granulomas, a condition found in 14 percent of the fish. The granulomas varied in severity, but had a consistent appearance in both organs. None of the granulomas contained visible parasites or fungi. They may have arisen from mycobacterial infection. One fish (#77) had an unusual number of immature leukocytes in its peripheral blood smear. The numbers of atypical cells were not high enough to warrant classification as a leukemia; the cause of the condition is unknown.

Largescale suckers form the Yakima River Canyon also appeared to be healthy. Only two recurring lesions of any significance were noted: acute dermatitis (described above), parasitic granulomas. Approximately 26 percent of the fish had hepatic and renal granulomas. These granulomas differed from those described at Horn Rapids in their anatomical location and in their morphology. The lesions at Horn Rapids co-occurred in kidney and spleen while these co-occured in kidney and liver. The granulomas in fish from the Canyon frequently bore multinucleated foreign-body giant cells and contained visible parasites. The parasitic organisms appeared as packets of spherical, darkly basophilic cells which often seemed to be intracellular, perhaps within a histiocyte. The organisms resembled members of the sporozoan group of protozoa; however, in histological section it was not possible to identify the organisms with certainty. Parasites morphologically identical to those found within the granulomas were also seen in the gills. In branchial tissues the organisms incited little or no inflammatory response.

No neoplastic lesions or idiopathic conditions that might be suggestive of contaminant exposure were found in suckers from either location.

The seventeen fish of assorted species that were collected at Horn Rapids bore no remarkable lesions. All appeared to be in generally good health, with the exception of minor parasitic or bacterial infections.

DISCUSSION

Fish sampled at two stations on the Yakima River bore no lesions that suggested widespread contaminant effects. The only organs that might warrant further research were the ovaries of common carp.

A significant number of female carp bore atretic (degenerating) ovarian follicles. Follicular atresia occurs when ovarian tissues are injured. If damage occurs during the process of vitellogenesis (yolk formation), the follicle cells typically acquire phagocytic properties, invade the oocytes, liquefy, and then absorb the yolk granules and ooplasm. If damage occurs after the completion of vitellogenesis, the follicle cells usually do not become phagocytic. Instead, the egg becomes opaque and its contents gradually dissolve. Among Yakima River fish, the second condition was more common.

Follicular atresia can be caused by a baffling array of factors including environmental conditions (e.g., water temperature, photoperiod, dissolved oxygen), nutritional deficiencies, endocrine disorders, parasitism, and contaminant exposure. Attempting to establish cause-and-effect relationships under field conditions would be a difficult and expensive undertaking.

In addition to the above-noted gonadal lesions, one hermaphrodite was found and one male had a benign testicular neoplasm (fibroma). All other organ systems in all species were either unremarkable or bore minor legions that could be attributed to parasitic and bacterial infections.

REFERENCES

Baumann, P.C., W.D. Smith, and M. Ribick, 1982. In: Polynuclear Aromatic Hydrocarbons: Physical an Biological Fate. M. Cooke, A.J. Dennis, and G.L. Fisher, Eds., pp. 93-102. Battelle, Columbus, OH.

Black, J.J., E.D. Evans, J.C. Harshbarger, and R. F. Zeigel, 1982. J. Natl. Cancer Inst. 69: 915-926.

Black, J.J., 1983. In: Polynuclear Aromatic Hydrocarbons: Formation, Metabolism and Measurement. M.Cooke and A.J. Dennis, Eds., pp. 99-111. Battelle, Columbus, OH.

Dawe, C.J., M.F. Stanton, and F.J. Schwartz, 1964. Cancer Research 24: 1194-1201.

Dawe, C.J. and J.C. Harshbarger, 1975. In: The Pathology of Fishes. W.E. Ribelin and G. Migaki, Eds. pp. 871-894. Univ. of Wisconsin Press, Madison, WI.

Malins, D.C., B.B. McCain, D.W. Brown, A.K. Sparks, and H.O. Hodgins, 1982. Chemical Contaminants and Abnormalities in Fish and Invertebrates from Puget Sound. National Oceanic and Atmospheric Administration, Tech. Memo. OMPA-19, 168 pp.

Smith, C.E., T.H. Peck, R.J. Klauda, and J.B. McLaren, 1979. J. Fish. Dis. 2: 313-319.

Sonstegard, R.A., 1977. Ann. N.Y. Acad. Sci. 298: 261-269.

GLOSSARY OF SELECTED TERMS

Atresia--Atresia (ovarian) is the degeneration or resorption of an ovarian follicle before it reaches maturity.

Basophilic--Basophilic refers to those components of a cell which have a staining affinity for alkaline (basic) dyes. The most commonly used basic dye is hematoxylin.

Fibroblast--A fibroblast is an immature fiber-producing cell of the connective tissue. Such cells are often found at sites of chronic inflammation or scar formation.

Granuloma--A granuloma is a tumor-like mass of chronic inflammatory tissue with actively growing fibroblasts and histiocytes. Granulomas are generally spherical and contain either a microorganism or a foreign body at their center.

Histiocyte--A histiocyte is a phagocytic cell. When these cells occur in solid tissues, they are called histiocytes or macrophages. When they occur in peripheral blood, they are called monocytes.

Histopathology--Histopathology refers to the application of light or electron microscopy to the study of tissue defects. This term contrasts with gross pathology which refers to examination of tissue defects with the unaided (naked) eye.

Idiopathic--An idiopathic disease or condition is one whose cause is unknown.

Mesangium--The mesangium is the thin membrane which supports the capillary loops of the renal glomerulus. In this report, an increase in the thickness of that membrane is referred to as increased mesangial density.

Neoplasm--A neoplasm (tumor) is a new growth of cells which proliferate autonomously and which serve no useful purpose.

Papilloma--A papilloma is a benign epithelial cell tumor growing from a surface. They are most often found on the skin and on the internal (luminal) surface of the gastrointestinal tract.

Pleomorphism--Pleomorphism refers to morphological variability. In the present study, the term was used to indicate the presence of variability in the diameter of hepatocellular cell nuclei.

Urolithiasis--Urolithiasis is the formation of urinary calculi (kidney stones). The calculi are usually abnormal concretions made of mineral salts.

KEY TO HISTOPATHOLOGY DATA TABLE

SPECIES

1 Common carp
2 Largescale sucker
3 Largemouth bass
4 Channel catfish
5 Northern squawfish
6 Chiselmouth
7 Goldfish
8 Smallmouth bass
9 Bridgelip sucker

SEX

1 Male
2 Female
0 Undetermined

ORGAN

0 All organs
1 Liver
2 Kidney
3 Spleen
4 Gill
5 Gonad
6 Blood
7 Skin

SEVERITY

1 Minimal
2 Mild
3 Moderate
4 Severe

LESIONS

001 No visible lesions
034 Trichodinid parasites
065 Follicular atresia
074 Unidentified protozoan parasite
124 Unidentified parasite
200 Inflammation
219 Granuloma
234 Mononuclear cell infiltrate
235 Dark macrophage infiltrate
261 Fibrosis
306 Increased glomerular mesangial matrix
309 Necrosis
356 Calcium deposits
359 Urolithiasis
406 Nuclear pleomorphism
482 Hepatocellular lipid vacuolization (NOTE: This is not a pathological condition, but rather it represents normal physiological variation.)
726 Increased numbers of melanin-macrophage centers
734 Regeneration
902 Cyst formation
905 Aneurysm
950 Vascular congestion
959 Hemorrhage

DISTRIBUTION

1 Focal
2 Multifocal
3 Diffuse

SITE	SPECIES	NUMBER	LENGTH (mm)	WEIGHT (g)	SEX	LESIONS	SEV	DIST
HORN RAPIDS DAM	1	1	425	1475	2	1-482	4	3
						1-234	1	2
		2	500	2100	1	1-482	4	3
						4-905	1	2
						4-034	1	2
		3	585	3580	2	1-482	4	3
						1-234	1	1
						1-074	1	1
						4-905	1	2
		4	549	2475	2	1-482	2	3
						2-219	1	2
						4-034	1	2
						5-065	3	2
		5	392	1060	1	1-482	2	3
		6	530	2430	1	1-482	4	3
						2-726	2	3
						4-905	1	1
		7	445	1650	1	1-482	4	3
						3-726	2	3
		8	425	1550	2	1-482	2	3
						1-234	3	1
						2-234	2	1

9	455	2000	2	1-482	2	3
				1-234	2	1
				2-234	2	1
				2-359	1	1
10	500	2100	2	1-482	3	3
				2-219	4	2
				2-306	2	2
				4-905	1	2
11	440	1600	2	1-482	2	3
				1-234	2	2
				2-234	2	2
				2-356	1	1
				2-219	1	1
				4-905	3	2
12	310	650	2	1-482	5	3
				1-234	2	2
				2-234	4	2
				4-905	1	2
				5-065	3	2
13	420	1550	2	1-482	4	3
				1-234	2	1
				2-234	1	2
				4-034	1	1
14	430	1500	1	1-482	3	3
				3-726	1	2
15	400	1200	1	1-482	3	3
				1-234	1	1
16	446	1800	2	1-482	2	3
				1-234	3	2
				3-950	1	2
				4-905	1	2

17	494	2490	2	1-482	2	3
				1-235	2	2
				2-726	3	3
				3-726	3	3
				4-234	1	1
				5-065	3	2
18	486	2150	2	1-482	1	3
				7-261	3	1
19	455	1700	1	1-482	2	3
				1-234	2	2
				1-235	2	2
20	470	1550	2	1-482	2	3
				1-235	2	2
				2-234	2	1
				5-065	3	2
21	450	1875	2	1-482	2	3
				1-234	2	1
				2-359	1	1
				2-219	2	2
22	465	1950	2	1-482	2	3
				1-235	2	2
23	380	950	2	1-482	3	3
				1-234	2	2
				2-219	1	1
				3-726	2	3
				4-074	1	1
24	386	1200	2	1-482	2	3
				2-219	1	1
25	550	3220	2	1-482	4	3
				4-905	1	2

26	506	2880	2	1-482	4	3
				1-234	2	2
				4-905	1	2
27	385	1650	1/2	1-482	5	3
				5-124	4	2
28	325	900	1	1-482	2	3
				1-234	1	1
				5-834	3	3
29	400	1800	2	1-482	3	3
				2-234	1	2
30	461	1999	1	1-482	4	3
31	424	1450	1	1-482	4	3
				1-234	1	2
				3-726	2	3
32	439	1625	1	1-482	3	3
				1-234	1	1
				3-726	2	3
33	405	1475	1	1-482	4	3
				2-234	3	1
34	470	2000	1	1-482	3	3
35	483	2405	2	1-482	3	3
				3-726	1	3
36	516	2050	2	1-482	3	3
				1-234	1	2
				4-034	1	1
37	525	3010	1	1-482	2	3
				1-726	3	3
				2-726	2	3
				4-034	1	2

38	478	2275	1	1-482	3	3
				1-726	2	3
				2-726	4	3
				3-726	4	3
				4-034	1	2
39	482	2470	2	1-482	3	3
40	475	2040	1	1-482	3	3
				2-726	2	3
				3-726	3	3
				4-905	1	2
41	380	1150	1	1-482	2	3
				1-200	2	1
				2-234	3	2
				2-356	2	2
42	376	1300	1	1-482	4	3
				1-234	2	2
				2-726	2	3
43	540	1800	2	1-482	2	3
				2-234	2	2
				2-200	2	1
				3-726	3	3
				4-034	1	2
44	325	800	1	1-482	2	3
				1-234	2	2
				4-905	2	2
45	390	1150	2	1-482	4	3
				4-034	1	2
46	321	550	2	1-482	2	3
				1-234	2	2
				2-219	2	2
				2-234	3	2
				2-356	1	1

		47	415	1425	1	1-482	4	3
						3-726	2	3
		48	450	1800	1	1-482	4	3
						1-234	2	1
						2-234	2	2
						4-034	1	2
		49	335	825	1	1-482	2	3
						1-234	2	2
						4-905	1	2
		50	330	850	1	1-482	2	3
						4-905	2	2
HORN RAPIDS DAM	2	51	470	1150	2	1-482	4	3
						1-309	3	2
		52	445	800	2	1-482	1	3
						1-219	3	2
						2-219	4	2
						3-219	4	2
		53	466	1100	2	1-482	2	3
						1-234	2	2
		54	435	1000	1	1-482	4	3
						1-234	2	1
						2-234	3	2
						3-950	2	3
		55	410	925	2	1-482	3	3
						3-950	2	3
						7-200	3	1

56	414	850	1	1-482	3	3
				3-950	3	3
				6-406	2	2
57	385	550	1	1-482	1	3
				1-234	3	2
				7-200	3	1
58	417	750	2	1-482	2	3
				1-234	2	2
				1-309	2	2
				3-950	2	3
59	470	1275	2	1-482	2	3
				1-234	2	2
60	505	1500	2	1-482	3	3
				3-726	2	3
61	530	2035	2	1-482	3	3
				2-219	3	2
				3-219	3	2
62	460	1250	2	1-482	2	3
				3-950	2	3
63	480	1450	2	1-482	4	3
64	425	825	1	1-482	4	3
				2-219	2	1
				3-219	2	1
65	455	1200	2	1-482	3	3
66	460	1175	2	1-482	2	3
				1-309	2	2
				2-726	2	3
67	460	1300	2	1-482	2	3

68	420	800	1	1-482	3	3
				3-726	1	3
69	445	1150	2	1-482	3	3
70	415	950	1	1-482	3	3
				3-950	2	3
71	469	1200	1	1-482	4	3
				2-219	4	2
				3-219	3	2
				3-726	2	3
				3-950	1	2
72	450	1050	2	1-482	2	3
				2-726	2	3
				3-219	2	2
73	415	900	1	1-482	3	3
				1-726	3	3
				1-219	2	1
				1-234	2	2
				1-074	2	1
				1-235	2	2
				2-726	2	3
				3-726	2	3
				4-905	1	2
74	480	1475	2	1-482	2	3
				1-234	2	1
				2-726	2	3
				2-219	2	1
				3-219	2	2
75	490	1500	2	1-482	3	3
				1-950	3	2
76	425	900	2	1-482	3	3
				1-234	2	2

77	415	1075	2	1-482	4	3
				1-234	2	2
				6-524	4	3
78	490	1600	2	1-482	3	3
				1-726	2	3
				1-235	2	2
				1-234	2	1
				2-726	2	3
				3-726	2	3
79	485	1400	2	1-482	1	3
80	490	1500	2	1-482	3	3
				1-950	2	3
				2-219	3	2
				3-219	3	2
81	460	1325	1	1-482	4	3
				1-950	3	3
82	435	1200	1	1-482	4	3
				1-950	2	1
				4-309	3	1
83	460	1100	2	1-482	2	3
				1-309	2	2
				6-406	2	2
84	465	1300	2	1-482	1	3
				1-234	2	2
85	345	700	2	1-482	2	3
				1-234	1	2
				2-356	1	2
				2-219	2	2
86	460	1200	2	1-482	3	3
				2-234	3	2

87	400	1050	1	1-482	3	3
88	469	1300	1	1-482	2	3
				1-309	2	2
				2-726	3	3
				2-219	3	2
				2-234	3	2
				3-219	2	1
89	445	1150	2	1-482	3	3
				2-219	2	1
90	470	675	1	1-482	4	3
				1-234	2	2
				4-905	2	2
91	412	1025	1	1-482	3	3
				1-234	3	2
				1-726	2	3
92	456	1550	2	1-482	4	3
				2-234	2	2
93	450	1425	2	1-482	3	3
				2-234	3	2
94	436	1225	1	1-482	3	3
				1-234	2	2
				1-309	2	1
				1-219	2	2
				3-950	3	3
95	470	800	2	1-482	3	3
				1-309	2	2
				1-234	2	1
				4-905	3	2

		96	455	1275	2	1-482	2	3
						1-219	2	1
						1-309	2	2
						2-726	2	3
						2-219	2	1
		97	443	1200	2	1-482	3	3
						3-726	2	3
						3-219	2	1
						4-905	2	2
		98	445	1150	2	1-482	2	3
						1-219	2	1
						2-726	2	3
						2-219	2	2
		99	430	1150	2	1-482	2	3
						1-234	2	2
		100	406	1150	1	1-482	4	3
						1-219	2	2
						2-210	2	1
YAKIMA CANYON	2	101	535	2105	2	1-482	4	3
						1-219	3	2
						2-219	3	2
						3-950	2	3
		102	440	1000	1	1-482	2	3
						1-234	2	2
						2-726	3	3
						2-234	2	1
		103	455	1325	1	1-482	4	3
						7-959	3	1

104	530	1825	2	1-482	3	3
				1-234	2	2
				1-074	1	1
				2-200	3	2
				3-950	2	3
105	435	975	2	1-482	4	3
				1-950	3	2
				2-219	2	1
106	450	1100	1	1-482	3	3
107	434	1025	1	1-482	3	3
				1-219	3	2
				1-234	2	1
				2-219	3	2
				3-950	2	3
				7-200	3	1
108	440	950	1	1-482	2	3
				1-234	2	1
				2-726	3	3
				7-200	3	1
109	455	1350	2	1-482	4	3
				1-219	3	2
				1-234	2	1
				2-219	3	2
				2-234	2	2
110	470	1350	2	1-482	4	3
				1-219	3	2
				2-219	3	2
				4-905	2	2
111	412	950	1	1-482	3	3
				2-219	2	1
				3-950	2	3
				7-200	3	1

112	475	1350	2	1-482	2	3
113	415	975	1	1-482	4	3
				2-219	1	2
				4-124	1	1
114	440	1100	1	1-482	4	3
				1-234	2	1
				1-219	2	2
				2-219	4	2
				4-905	3	2
115	485	1400	2	1-482	3	3
				4-905	1	2
				7-200	3	1
116	677	625	1	1-482	2	3
				1-219	3	2
				1-234	2	2
117	565	2345	2	1-482	3	3
				4-200	2	1
118	505	1850	2	1-482	4	3
				1-219	3	2
				1-234	2	2
				2-219	4	2
				4-219	2	2
119	502	1975	2	1-482	4	3
120	512	1850	2	1-482	4	3
				1-219	3	2
121	410	775	2	1-482	3	3
				1-234	2	2
122	465	1375	2	1-482	4	3
				1-219	3	2
				4-124	1	1

123	510	1350	2	1-482	1	3
				1-4825	4	2
				7-200	3	1
124	545	2205	2	1-482	4	3
				4-124	2	2
125	510	1475	2	1-482	3	3
				1-074	2	2
				1-219	2	2
				2-219	3	2
				4-124	2	2
				7-200	3	1
126	427	900	2	1-482	4	3
				1-234	2	1
				7-200	3	1
				7-219	2	1
127	485	1375	2	1-482	3	3
				1-219	2	1
				2-726	2	3
128	450	1150	2	1-482	4	3
				2-234	2	2
				4-124	2	2
129	465	1100	1	1-482	4	3
				1-219	2	2
				3-726	2	4
				4-124	2	2
130	520	1900	2	1-482	4	3
				4-124	2	2
131	435	1100	1	1-482	4	3
				1-219	3	2
				2-219	4	2
				2-124	4	2
				4-124	2	2
				7-200	3	1

132	525	1800	2	1-482	4	3
				2-124	4	2
				2-219	3	2
				4-124	2	2
133	535	2025	2	1-482	3	3
134	487	1600	2	1-482	4	3
				4-124	2	2
135	516	1550	2	1-482	2	3
				1-124	2	2
136	503	1775	2	1-482	4	3
137	495	1500	2	1-482	4	3
				1-219	3	2
				2-124	2	2
				2-219	3	2
				4-124	2	2
138	455	1250	2	1-482	4	3
				1-219	2	2
				4-905	2	2
139	525	1575	2	1-482	2	3
				1-902	3	1
				4-124	2	2
140	445	1200	1	1-482	4	3
				1-219	3	2
141	495	1450	2	1-482	3	3
142	434	975	1	1-482	3	3
				1-309	2	2
				2-356	2	2
				7-200	3	1
143	510	1500	2	1-482	4	3
				4-124	2	2

144	535	1750	2	1-482	1	3
				1-074	2	1
				1-4825	3	2
				2-726	2	3
				2-124	3	2
				4-219	2	2
145	440	1225	1	1-482	4	3
				1-219	3	2
146	405	825	1	1-482	4	3
				2-219	3	2
				2-124	2	2
147	522	1950	2	1-482	4	3
				1-219	3	2
				1-234	2	1
				3-959	4	3
148	461	1125	2	1-482	3	3
				2-219	3	3
				4-124	2	2

		149	385	775	1	1-482	4	3
		150	420	875	2	1-482	3	3
						1-234	2	2
HORN RAPIDS DAM	3	151	316	450	1	1-482	2	3
						1-734	2	2
	3	152	200	120	1	1-482	2	3
						1-234	2	1
						2-902	3	1
						4-034	1	1
	4	153	360	525	2	1-482	2	3
						1-234	2	2
	5	154	315	375	1	1-482	3	3
						2-219	3	1
	5	155	236	160	0	1-482	3	3
						1-234	2	2
						1-075	2	1
	5	156	213	120	0	1-482	4	3
						1-309	3	1
	5	157	200	90	0	1-482	4	3
						2-219	2	2
	5	158	300	286	0	1-482	3	3
	6	159	212	111	0	1-482	1	3
						1-234	2	2
	3	160	193	99	0	1-482	1	3
						4-905	1	1

4	161	378	700	2	1-482	1	3
7	162	255	340	0	1-482	1	3
					1-309	3	2
					1-234	2	2
					2-219	2	1
					4-200	2	1
5	163	200	99	0	1-482	2	3
					4-905	2	1
3	164	185	92	1	1-482	1	3
					4-124	1	2
1	165	458	2135	2	1-482	3	3
					2-219	2	1
					2-356	1	2
					4-034	1	1
8	166	220	155	2	1-482	2	3
					4-905	1	1
9	167	402	675	0	0-001	-	-